



VETCT
CONSULTANTS IN TELEMEDICINE

IT'S YOUR CASE

Species: Canine

Breed: Crossbreed, medium Sex: Female Neutered

Age: 1 year

Clinical History:

She has a history of left thoracic limb of unreported duration. She is painful on palpation of the shoulder.

Details of study and technical comments:

A study of the left shoulder is presented for evaluation. The study consists of mediolateral and craniocaudal views.

Diagnostic interpretation:

LEFT SHOULDER:

The caudal third of the subchondral bone of the humeral head is flattened. There is mild heterogeneity of the adjacent epiphysis. A thin linear mineral opacity parallels the plane of the described region of the humeral head (image below, green arrows). The opacity of the caudal aspect of the humeral head is slightly heterogeneous (image below, red arrows).

Subtly increased mineral opacity overlies the intertubercular groove and there is faint mineral cranial to the supraglenoid tubercle (image below, blue arrows).

Mild periarticular remodelling is observed on the craniocaudal view (images below, right).

The joint space contains a small volume of gas, which outlines the articular cartilage.

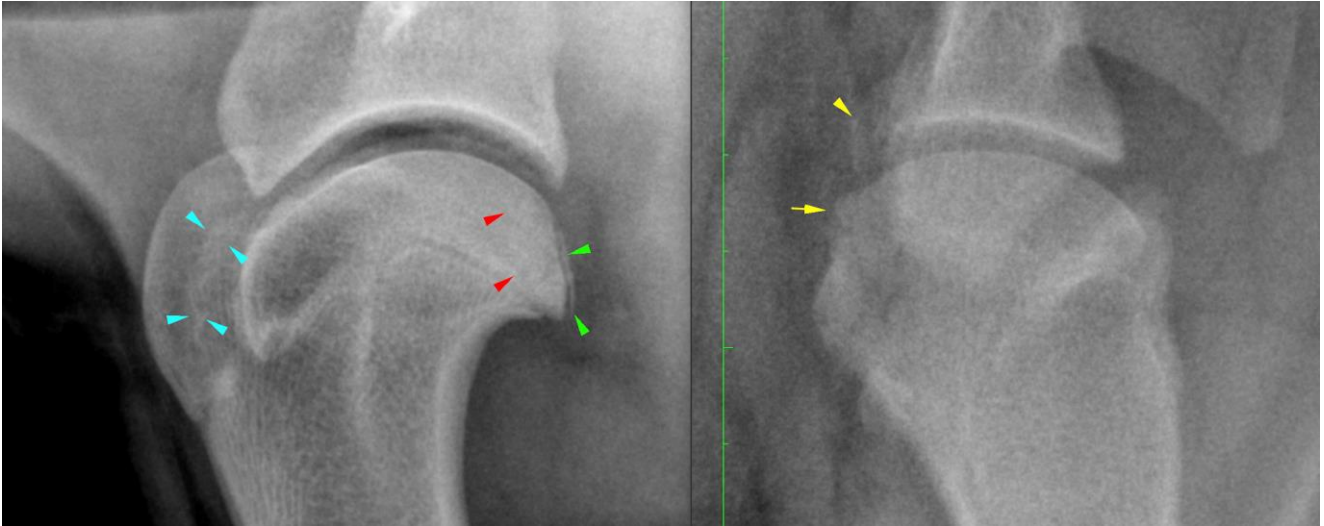


Reported by VetCT

t. +44 (0)1223 422251 www.vet-ct.com e. info@vet-ct.com

Co Number 6955449 Registered Office St John's Innovation Centre Cowley Road Cambridge CB4 0WS UK
ABN 24601862220 Registered Office in Australia Suite 11, 185-187 High Street Fremantle WA 6160 Australia

This report is based on the available history and radiographic interpretation only and not on a physical examination of the patient. It must therefore only be interpreted by a currently licensed and registered veterinary surgeon responsible for the care of this patient.



Conclusions:

- Osteochondritis dissecans (OCD).
- Intertubercular sclerosis is suggestive of degenerative joint disease. Concomitant bicapital tenosynovitis is a possibility.
- Mild secondary degenerative joint disease.
- Vacuum phenomenon.

Additional comments:

The OCD lesion is the likely cause of the described lameness. Osteochondrosis lesions are frequently bilateral. For this reason, radiography of the contralateral joint is recommended.

Osteochondrosis is a developmental disease in which the subchondral bone does not mineralize appropriately. This results in reduced support of the overlying cartilage and leads to mineralization. When the mineral flap breaks, the condition transitions to osteochondritis dissecans.



Reported by VetCT

t. +44 (0)1223 422251 www.vet-ct.com e. info@vet-ct.com

Co Number 6955449 Registered Office St John's Innovation Centre Cowley Road Cambridge CB4 0WS UK
ABN 24601862220 Registered Office in Australia Suite 11, 185-187 High Street Fremantle WA 6160 Australia

This report is based on the available history and radiographic interpretation only and not on a physical examination of the patient. It must therefore only be interpreted by a currently licensed and registered veterinary surgeon responsible for the care of this patient.