



VETCT
CONSULTANTS IN TELEMEDICINE

IT'S YOUR CASE

Species: Canine

Breed: Golden Retriever

Sex: Male Neutered

Age: 10 years

Clinical History:

Met Check for possible prostatic carcinoma.

Anatomic regions: Thorax

Details of study and technical comments: A radiographic study of the thorax is presented for evaluation. The study consists of right and left lateral views as well as a ventrodorsal view.

Diagnostic interpretation:

THORAX:

The patient has an increased body habitus. The lungs are hypoinflated on all views. The cardiac silhouette is normal in size and position; there is no specific chamber enlargement. The pulmonary vasculature is normal in diameter and tapers as it extends to the periphery. On the right lateral view, a 1.5 cm round soft tissue opaque nodule (red arrows) overlies the cardiac silhouette in the third intercostal space and is contiguous with the skinfold of the axilla. On the left lateral view, this is suspected to superimpose the distal aspect of the third rib pair (orange arrows). It not visible on the ventrodorsal view. A small soft tissue nodule is in the dorsal aspect of the eighth intercostal space on the left lateral view and measures 6 mm (yellow arrow). A second soft tissue nodule in the ventral aspect of the left caudal lung lobe, overlies the diaphragm (green arrows); it measures 7 mm in diameter. The trachea and mainstem bronchi are patent. The pleural space and mediastinum are unremarkable.

Mild multifocal spondylosis deformans is present in the thoracic vertebral column without evidence of fracture, luxation or osteolysis. Mild remodelling is associated with the caudal humeral head and glenoid bilaterally. The cranial abdomen has good serosal contrast. The visible margins of the liver are radiographically normal. The gastric silhouette contains gas and heterogeneous soft tissue ingesta.



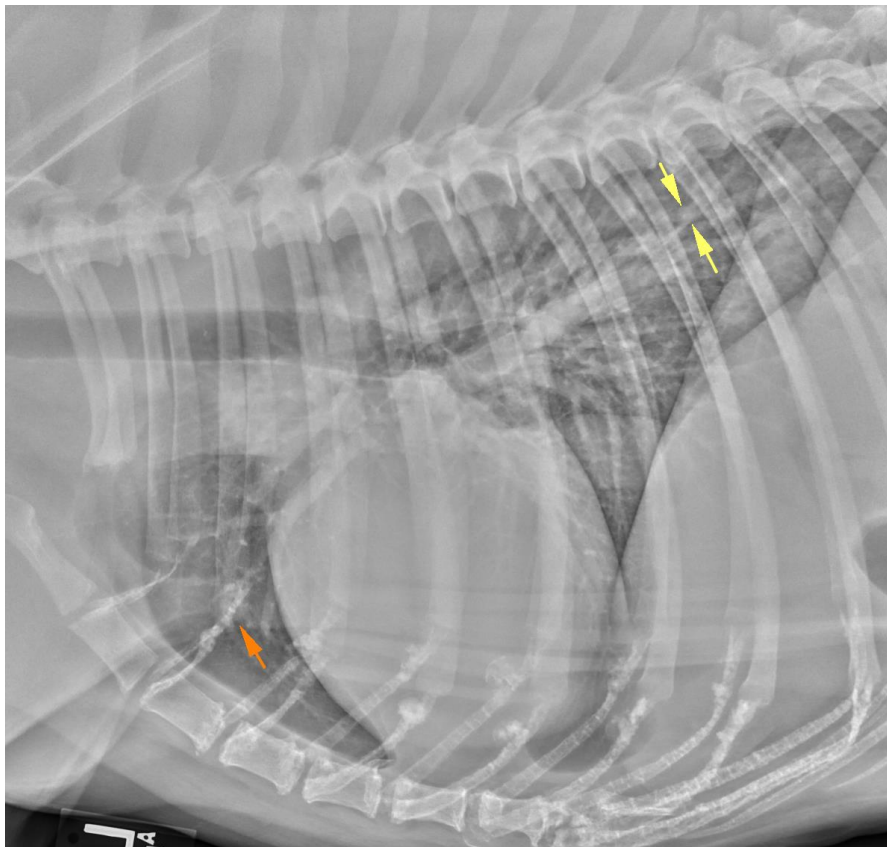
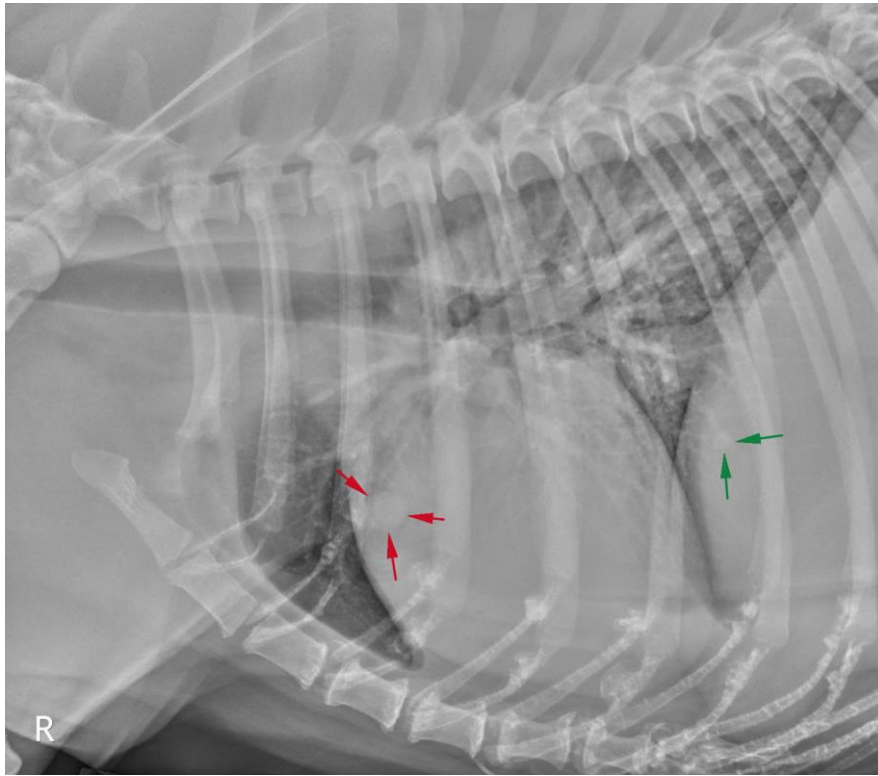
Reported by VetCT

t. +44 (0)1223 422251 www.vet-ct.com e. info@vet-ct.com

Co Number 6955449 Registered Office St John's Innovation Centre Cowley Road Cambridge CB4 0WS UK

ABN 24601862220 Registered Office in Australia Suite 11, 185-187 High Street Fremantle WA 6160 Australia

This report is based on the available history and radiographic interpretation only and not on a physical examination of the patient. It has been prepared specifically for interpretation by the currently licensed and registered veterinary surgeon responsible for the care of this patient.



Conclusions:



Reported by VetCT

t. +44 (0)1223 422251 **www.vet-ct.com** **e.** info@vet-ct.com

Co Number 6955449 Registered Office St John's Innovation Centre Cowley Road Cambridge CB4 0WS UK
ABN 24601862220 Registered Office in Australia Suite 11, 185-187 High Street Fremantle WA 6160 Australia

This report is based on the available history and radiographic interpretation only and not on a physical examination of the patient. It has been prepared specifically for interpretation by the currently licensed and registered veterinary surgeon responsible for the care of this patient.

Two small soft tissue nodules of the caudal lung lobes. Differentials include pulmonary metastasis vs granuloma.

Soft tissue nodule overlying the cardiac silhouette is likely cutaneous.

Additional comments:

Further consideration of the soft tissue nodule overlying the cardiac silhouette can be made with physical exam, palpating along the caudal cutaneous margins of the brachia. If identified, barium paste can be applied and repeated radiography can be performed with similar positioning.

The soft tissue nodules of the caudal lung lobes may represent early metastasis, however pre-existing granulomas can not be fully excluded. Repeat radiographs with improved inspiration, recheck radiographs to monitor for progression, or computed tomography could be considered as additional steps.



Reported by VetCT

t. +44 (0)1223 422251 **www.vet-ct.com** **e.** info@vet-ct.com

Co Number 6955449 Registered Office St John's Innovation Centre Cowley Road Cambridge CB4 0WS UK

ABN 24601862220 Registered Office in Australia Suite 11, 185-187 High Street Fremantle WA 6160 Australia

This report is based on the available history and radiographic interpretation only and not on a physical examination of the patient. It has been prepared specifically for interpretation by the currently licensed and registered veterinary surgeon responsible for the care of this patient.